

**Purépecha Biohistory Project:  
A Differential Diagnosis on Burial 14.2  
A Possible Case of Hypertrophic Osteoarthropathy**

**Eli Mrak**

**Honors Thesis**

**Mentored by Dr. Melissa Murphy**

**University of Wyoming**

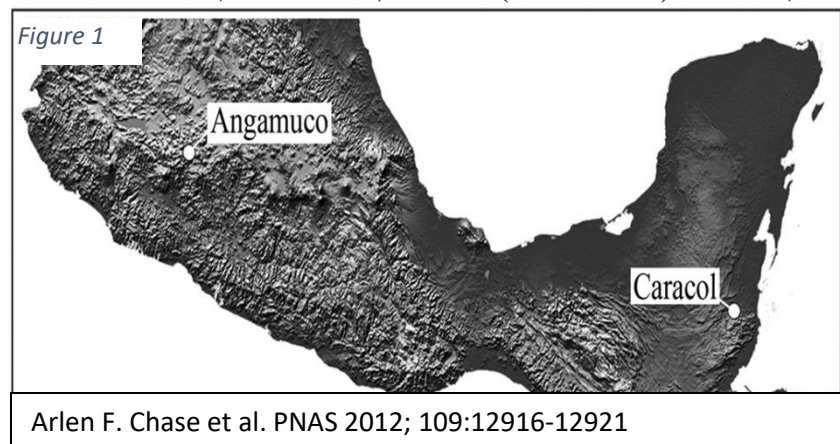
**Fall Semester 2017**

## Abstract

The well preserved skeletal remains of a young adult female from the pre-Hispanic city of Angamuco, Michoacán, Mexico were analyzed during the Purépecha Biohistory Project in May of 2016. The bones of this individual display an array of proliferative new bone formation (PNBF) in the form of extensive periosteal reaction to the majority of the elements present. A differential diagnosis was conducted based on the types of lesions present and their distribution on the individual's skeleton. Osseous responses similar to that observed on this individual have been credited to a variety of diseases such as cardiovascular disease, gastrointestinal disease, hepatobiliary disorders and endocrine disorders; thus complicating the diagnosis of a particular disease. However, through the analysis of several different diseases and their involvement of the skeleton, a diagnosis of hypertrophic osteoarthropathy appears to be the most applicable to this case.

## Project Background

In a 2013 article, Dr. Chris Fisher discusses the way that he and numerous colleagues have work over the last decade in western Mexico to better comprehend the temporal associations and spatial arrangement of the Purépecha city of Angamuco, located within the Lake Pátzcuaro Basin, Michoacán, Mexico (Fisher 2013). In 2014, Dr. Fisher begin excavations on a



portion of a cemetery found within the city. Through the excavation of the cemetery, he was interested in examining changes in health, status and well-being during a

period of rapid social change that is associated with the formation of the Purépecha Empire (Fisher 2013). The burials recovered during the project are representative of the pre-Hispanic Purépecha population. The Purépecha were contemporaries and rivals of the Aztecs in central Mexico. Considered the most advanced metalsmiths and having created some of the finest crafts in Mexico, the Purépecha were one of the few cultures that was able to resist the spread of Aztec power, maintaining their cultural autonomy (Fisher 2005). The city of Angamuco and the burials examined date to the middle to late Post-Classic Period (AD 1000-1520).




Image illustrating one way LiDAR data can be visualized from the city of Angamuco, Michoacán, Mexico. Image depicts hillshade displayed as a 3-D image of the DSM that was created from LiDAR data. Ancient structures, walls, roads, pyramids and other features are clearly displayed. Photo Courtesy of Dr. Chris Fisher: *LiDAR at Angamuco*

Like the Aztec, the Purépecha Empire was destroyed following European occupation in the early 1500s. Examinations of the remains recovered by Dr. Fisher and his crew will aid in developing a more complete view of the Purépecha civilization and the overall occupation of the site. The discovery of the cemetery and the subsequent analysis of the interred,

also provides the potential for new insights into the funerary practices of the ancient Purépecha. The burials were discovered within a large plaza dominated by a traditional Purépecha keyhole-shaped pyramid and associated large altars. Most of the burials, with numerous incomplete skeletons, along with evidence of cremations, were discovered in “flexed” positions either in

formal small tombs or in pits (Fisher 2005). In total, Dr. Fisher's excavations revealed 37 complete individuals and a minimum of 61 sets of partial remains (Fisher 2013).

In 2016, Dr. Fisher asked Dr. Melissa Murphy, a bioarchaeologist and professor at the University of Wyoming, if she would travel to Mexico City where the individuals excavated from Angamuco were being curated, and complete a full osteological analysis of the remains. She agreed and chose three students to accompany her on the project. I was one of the students who had the opportunity to attend. At the end of May in 2016, we traveled to Mexico City to work on the Purépecha Biohistory Project at the Centro de Estudios Mexicanos y Centroamericanos (CEMCA).

During the Purépecha Biohistory Project, one of the sets of remains I analyzed was that of a well preserved young adult female from Angamuco. The bones of this individual displayed



Figure 3  
Fellow student and myself analyzing burials from Angamuco at the Centro de Estudios Mexicanos y Centroamericanos (CEMCA) in Mexico City. Photo Courtesy of Dr. Melissa Murphy

an array of proliferative new bone formation to the majority of the elements present. From the skeletal analysis, a differential diagnosis was conducted based on the types of lesions and their distribution on the individual.

Osseous responses similar to that observed on this individual have been credited to numerous underlying diseases such as scurvy, leprosy, hypervitaminosis A, thyroid acropachy, and various cardiovascular

diseases, gastrointestinal disease, hepatobiliary disorders and endocrine disorders. With so many potential pathognomonic sources, diagnosis of a particular disease becomes quite complicated.

However, the totality of evidence suggests an underlying chronic condition, of which, the likelihood of secondary hypertrophic osteoarthropathy as a result of a non-malignant lung neoplasm is the most probable cause for the lesions witnessed.

### **Pathological Descriptions**

This individual has excessive amounts of periosteal reactions and abnormal bone growth on almost every skeletal element present. Affected elements included the posterior portion of the medial end of the right clavicle, scapular fossa, supraspinous fossa and infraglenoid tubercle of the right scapula, acromion of the right scapula, posterodistal diaphysis of the right humerus, medial epicondyle of the right humerus, right radial head, right radial shaft inferior to radial tuberosity, distal end of right radius, the entire right ulna with spicules present near radial notch and distal diaphysis, inferior gluteal line of the right innominate, posterior to the right acetabulum, proximal end of the right femur including femoral head, right femoral diaphysis, the entire right tibia, sternal end of first right rib, scapular fossa, supraspinous fossa and scapular spine of the left scapula, along the diaphysis of the left humerus, radial tuberosity, radial shaft and distal end of the left radius, entire left ulna, second, third, fourth, and fifth left metacarpals, medial aspects of four proximal hand phalanges, posterior iliac blade, diaphysis, lesser trochanter, and medial epicondyle of the left femur, diaphysis and onto the medial malleolus of the left tibia, diaphysis of the left fibula, between sustentacular sulcus and processes of the left calcaneus, left first metatarsal, first foot phalange, two right metatarsals, and the third and fourth left metatarsals.

The diaphyses of the majority of present long bones show an “onion peel” appearance, where the reactive bone growth appears as a sheathing along the shaft (Ortner 3003). In areas of muscle attachment sites and joints, abnormal bone growth gives a spicule appearance. Without

radiographic evidence for this individual, it is difficult to determine disruptions in the osteoblastic and osteoclastic activity ratios. However, in areas where the periosteal sheathing has been broken away, macroscopic analysis did not reveal a great deal of change to the underlying cortical bone. For examples, see figure 4.



Burial 14.2 Examples of PNBF: Top Left: Lateral right 5th metacarpal demonstrating layered periostitis. Top Right: Lateral view of right innominate with PNBF along gluteal line. Bottom: Diaphysis of right femur showing layered and “peeling” of periostitis. Note unaffected cortical bone below the pealed portion of the periosteal reaction. Photos Courtesy of Dr. Melissa Murphy



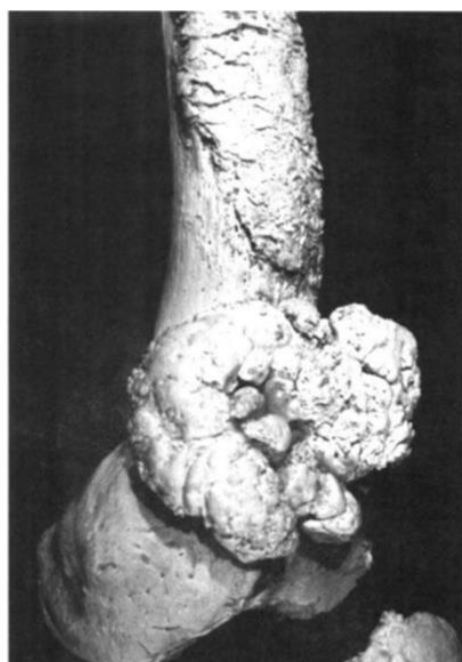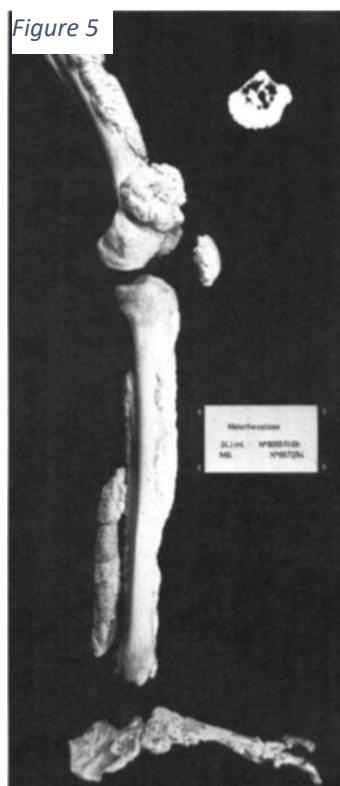## Periostitis

Periostitis and its general presence witnessed as abnormal bone formation is often caused by infection, trauma, cancer, vascular impairments or a variety of other conditions (Ortner 2003; Resnick 1995). Periostitis signifies inflammation which can be caused by infectious or non-infectious conditions. When the underlying cause of the periosteal reaction is unknown, the term periostosis is generally applied (Ortner 2003). This denotation is important to better define cases

described by increased periosteal bone formation such as those caused by pachydermoperiostosis or Touraine-Solente-Golé syndrome also known as Primary Hypertrophic Osteoarthropathy. 3–5% of all cases of hypertrophic osteoarthropathy are attributed to this particular condition (González-Reimers et al. 2015). Periostitis can be primary or secondary, however in each case they are nonspecific indicators of disease. In the case of individual 14.2, there are a variety of periosteal reaction types. The distribution and unique characteristics of these lesions are helpful in teasing out the certain etiologies attributed to the underlying disease.

### Melorheostosis

Melorheostosis is a known pathological condition which results in periosteal changes to the skeleton (Christensen 2013). Melorheostosis is described as a non-genetic, benign sclerosing bone disease where new cortical bone is laid down in a succession of layers creating a flowing candle wax appearance (Wadhwa 2014, Ortner 2003). Often characterized by a monomelic



Example of bone involvement in a case of melorheostosis.  
Photo Credit Ortner 2003

distribution of bony lesions, melorheostosis' involvement of the skeleton is unilateral, segmental and will mostly affect the bones of a single limb (Wadhwa 2014). Furthermore, it is most commonly observed on the lower limbs, and in rare occasions exhibits lesions on the vertebra and the crania.

The bilateral involvement and diffusely distributed bony lesions on individual 14.2's bones do not align with the diagnostic characteristics of melorheostosis. Therefore, it is unlikely to be the cause of the multitude of lesions seen on individual 14.2.

### ***Mycobacterium tuberculosis***

*Mycobacteria* infections are also necessary to consider in the differential diagnosis of this case. *Mycobacterium tuberculosis* is most commonly acquired through inhalation of the tuberculosis bacilli. Once infection of the lung has occurred, tuberculosis can cause acute pneumonia or chronic pulmonary disease (Christensen 2013). After initial infection tuberculosis bacilli later harbor into local macrophages where they remain in a quiescent phase (González-Reimers 2015). As the infection persists, bacilli are spread through the bloodstream which eventually leads to the infection of organs such as the kidneys and bones (González-Reimers 2015; Christensen 2013). Unlike the lesions seen on individual 14.2, tuberculosis infection involves the proximal and distal ends of long bones and spreads to the joints. Skeletal involvement of tuberculosis is accompanied by intense osteoporosis causing distinct lesions, destruction of cancellous bone and sequestra formation (González-Reimers 2015; Kelly et al. 1991). All these alterations are absent in the case of individual 14.2, therefore we can likely exclude bone tuberculosis.

### ***Treponemia pallidum pertenue* (Yaws)**

Yaws, a contagious treponemal disease that occurs primarily in humid tropical regions, is the result of infection by the bacteria *Treponemia pallidum pertenue* (González-Reimers 2015; Mitjá et al. 2011). The bones of living individuals infected with yaws have been documented to undergo periostitic changes which have been shown to appear in a specific manner (Mitjá et al.

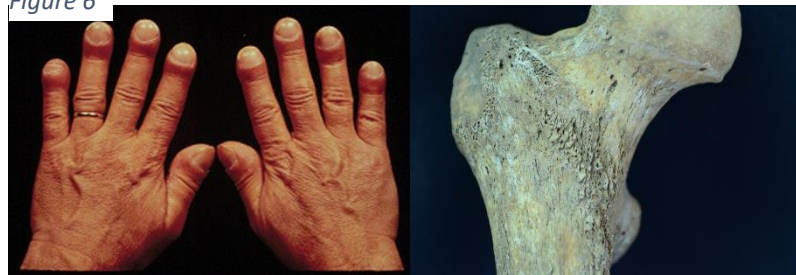

2011). The affected bones of individuals with yaws will display a polyostotic distribution of bone involvement (González-Reimers 2015; Mitjá et al. 2011). One defining characteristic of yaws' skeletal involvement is the non-diffuse and localized distribution of lesions (González-Reimers 2015). Although individual 14.2 is from an area where Yaws has been documented in both living and archeological specimens, the diffuse distribution of lesions analyzed are an indication that *Treponemia pallidum pertenuis* is an unlikely cause.

### **Hypertrophic osteoarthropathy**

Hypertrophic osteoarthropathy (HOA) is a syndrome of clubbing of the digits, periostitis of the long bones, and arthritis. There are two recognized forms of HOA. Primary hypertrophic osteoarthropathy (PHOA) or pachydermoperiostosis (PDP) is a rare genetic disorder that affects both bones and skin. Other names for PHOA are idiopathic hypertrophic osteoarthropathy or Touraine-Solente-Golé syndrome (Martínez-Lavín & Pineda 2008; Armstrong et al. 2007). In living individuals PHOA is largely characterized by pachydermia, periostosis of the tubular bones, finger clubbing and arthritis. (Ito 2010; Martinez-Lavin M, Vargas A & Rivera-Vinas M.

Figure 6



Left Photo: Example of digital clubbing from modern case of HOA. Photo Courtesy of lookforfree.com  
Right Photo: Individual 14.2 right femur example of possible osteoarthritis often seen in HOA cases. Photo Courtesy of Dr. Melissa Murphy

2008). For purposes of developing a differential diagnosis, physiologic disruptions that leave markers on the bones will be the primary focus of the HOA disease process. Some patients with

primary hypertrophic osteoarthropathy eventually develop diseases such as patent ductus arteriosus, Crohn's disease and myelofibrosis, which are otherwise known to be underlying

causes of the secondary type of hypertrophic osteoarthropathy (Ntaios et al. 2010; Cohen AM et al. 1986).

Much like the primary form of HOA, the secondary form is characterized by proliferative changes in the skin and skeleton. Secondary HOA was initially described in association with chronic suppurative infection and malignancy of the lungs and pleura (Touraine A, Solente G, Gole L.1935). Since HOA was first documented, it has been associated with numerous disease processes, including cardiovascular disease, gastrointestinal disease, hepatobiliary disorders and endocrine disorders (Fridlington 2007). Proliferative periostitis of the long bones,

oligopolysynovitis (over production of synovial fluids), and digital clubbing are also commonly

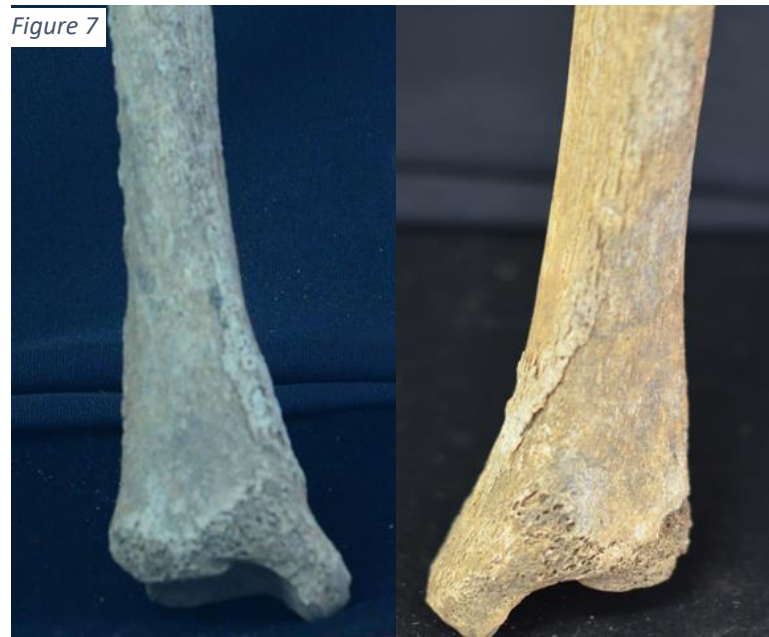

Figure 7

Posterior right and left distal tibiae of individual 14.2 displaying bilateral distribution of periostitis. Photos Courtesy of Dr. Mellissa Murphy

seen in individuals with HOA (Ito 2010; Martinez-Lavin et al., 1994).

On skeletal remains, periosteal new bone formation is the most useful diagnostic indicator of HOA (Ito 2010; Christensen 2013).

Typically, HOA results in bilateral and symmetrical patterns of bone formation seen in affected skeletal

elements (Assis, Santos & Roberts 2011; Martínez-Lavín 2007; Ortnor

2003). Involvement of long and short tubular bones are the most common however, studies have shown the potential for other bones to be involved in HOA such as the skull, scapulae, patellae, ribs, and the iliac and pubic bones (Ali et al., 1980). Although non-involvement of the joints has

been described as a distinctive feature of HOA, the effects of the over production of synovial fluids can lead to inflammation and osteoarthritis in these areas (Martínez-Lavín, 2007; Bathurst and Barta, 2004). Macroscopically, the periosteal new bone deposition presents ‘a dense and



Top Photo: Individual 14.2 left ulna displaying “dense and lumpy” periosteal reaction.  
Bottom Photo: Individual 14.2 right radius displaying multi-layered and laminated periosteal reaction.  
Photos Courtesy of Dr. Melissa Murphy

lumpy’ appearance (Ortner, 2003) with a multi-layered laminated structure. The proliferative periostosis associated with secondary HOA can result in a thin, fibrous layer which may separate newly formed bone from the underlying cortical bone (Martínez-Lavín, 2007; Ortner, 2003).

Radiographically, the periostosis appears as a single lamination of new bone upon to the bone cortex which displays a smooth or ‘onion-skin’

appearance (Christensen 2013; Ortner 2003). Periosteal bone formation in secondary HOA will typically affect the distal aspects of the extremities and as the disease persists, PNBF proliferation will progress centrally (Christensen 2013; Fridlington 2007; Martínez-Lavín 2007). Chronic lung diseases have been attributed to most cases of HOA evident in ancient remains (Christensen 2013). In the case of individual 14.2, the marked periosteal thickening and the presence of mature lamellar bone suggests that a chronic nonmalignant disease of the lungs was likely the underlying etiology.

## Conclusion

Based on the differential diagnosis completed for this project, some of the diseases investigated appear improbable as the cause of the pathologies present on the individual from burial 14.2. Primary Periostitis, Melorheostosis, *Mycobacterium tuberculosis* and *Treponema pallidum pertenue* have all been previously revealed to result in bony lesions unlike those witnessed on the examined skeleton. The intense periosteal reaction present on this individual suggests that HOA was probably related to a secondary condition, perhaps a lung neoplasia, which seem to be the most frequent etiology in modern times. In future diagnostic work on this case, radiological examination will be crucial for the interpretation of the suggested underlying pathology since it allows confirmation of the absence of cancellous bone affectation and the non-obliteration of the bone marrow cavity, which would provide further evidence supporting a diagnosis of secondary HOA.

## References

- A. M. Cohen, B. S. Yulish, K. B. Wasser, P. J. Vignos, P. K. Jones, S. B. Sorin *Am J Dis Child.* (1986). Evaluation of Pulmonary Hypertrophic Osteoarthropathy in Cystic Fibrosis. A Comprehensive Study. Jan; 140(1): 74–77.
- A. Ali, M.R. Tetalman, E.W. Fordham, D.A. Turner, J.T. Chiles, S.L. Patel, K.D. Schmidt. (1980). Distribution of Hypertrophic Pulmonary Osteoarthropathy. *Am. J. Roentgenol.* 134 (4), pp. 771-780
- Armstrong DJ, McCausland EMA, Wright GD. (2007). Hypertrophic pulmonary osteoarthropathy (HPOA) (Pierre Marie-Bamberger Syndrome): Two cases presenting as acute inflammatory arthritis. Description and review of the literature. *Rheumatology International* 27:399–402. DOI:10.1007/s00296-006-0224-2.
- Assis, S., Santos, A. L., & Roberts, C. A. (2011). Evidence of Hypertrophic Osteoarthropathy in Individuals from the Coimbra Skeletal Identified Collection (Portugal). *International Journal of Paleopathology*, 1(3-4), 155-163. doi:10.1016/j.ijpp.2012.02.009
- Bathurst, R. R., & Barta, J. L. (2004). Molecular Evidence of Tuberculosis Induced Hypertrophic Osteopathy in a 16th-century Iroquoian Dog. *Journal of Archaeological Science*, 31(7), 917-925. doi:10.1016/j.jas.2003.12.006
- Christensen, T., Martínez-Lavín, M., & Pineda, C. (2013). Periostitis and osteolysis in a medieval skeleton from South-West Hungary: (leprosy, treponematosi, tuberculosis or hypertrophic osteoarthropathy) A diagnostic challenge. *International Journal of Osteoarchaeology*, 23(1), 69-82. doi:10.1002/oa.1240
- González-Reimers, Emilio, Aioze Trujillo-Mederos, Manuel Machado-Calvo, María Castañeyra-Ruiz, Alejandra C. Ordóñez, and Matilde Arnay-de-la-Rosa. "A Skeletal Case of Hypertrophic Osteoarthropathy from the Canary Islands Dating from 1000 BP." *International Journal of Paleopathology* 11, (2015): 1-6.
- Fisher, C. T. (2005). Demographic and Landscape Change in the Lake Pátzcuaro Basin, Mexico: Abandoning the Garden. *American Anthropologist*, 107(1), 87-95. doi:10.1525/aa.2005.107.1.087
- Fisher, C.T., H. P. Pollard, I. Israde-Alcántara, V. H. Garduño-Munroy, S. Banerjee. (2013) A Reexamination of Human Induced Environmental Change Within the Lake Pátzcuaro Basin, Michoacán, Mexico. *Proceedings of the National Academy of Sciences* 100 (8) 4957-4962.
- Fridlington, J. (2007). Secondary hypertrophic osteoarthropathy associated with solitary fibrous tumor of the lung. *Journal of American Academy of Dermatology*, 57(5 Suppl), S106-S110. doi:10.1016/j.jaad.2006.10.045
- Ito, Takeo. Hypertrophic Pulmonary Osteoarthropathy as a Paraneoplastic Manifestation of Lung Cancer. *Journal of Thoracic Oncology*. 2010 5(7):976-980.

Kelly, P., Manning, P., Corcoran, P., & Clancy, L. 1991. Hypertrophic osteoarthropathy in association with pulmonary tuberculosis. *Chest*, 99(3), 769-770. doi:10.1378/chest.99.3.769  
Martinez-Lavin, M. 2007. Exploring the cause of the most ancient clinical sign of medicine: Finger clubbing. *Seminars in Arthritis and Rheumatism*, 36(6), 380-385. doi:10.1016/j.semarthrit.2006.11.004

Martínez-Lavín M, Pineda C. 2008. Digital Clubbing and Hypertrophic Osteoarthropathy. In *Rheumatology*, Hochberg MC, Silman AJ, Smolen JS, Weinblatt ME, Weisman MH (eds). Elsevier Mosby: St. Louis;1683–1687.

Martínez-Lavín, M., Mansilla, J., Pineda, C., Pijoán, C., Ochoa, P., 1994. Evidence of hypertrophic osteoarthropathy in human skeletal remains from pre-Hispanic Mesoamerica. *Ann. Intern. Med.* 120, 238–241.

Martinez-Lavin M, Vargas A, Rivera-Vinas M. Hypertrophic osteoarthropathy: a palindrome with a pathogenic connotation. *Curr Opin Rheumatol.* 2008 Jan. 20(1):88-91.

Ortner, DJ. 2003. *Identification of Pathological Conditions in Human Skeletal Remains* (2nd edn). Academic Press: San Diego.

Resnick D, Niwayama G. 1995. Enostosis, Hyperostosis and Periostitis. In *Diagnosis of Bone and Joint Disorders*, Resnick D (ed.). Saunders: Philadelphia, PA

Touraine A, Solente G, Gole L. Un syndrome osteodermopathique: La pachydermie plicaturee avec pachyperiostose des extremités. *Presse Med.* 1935. 43:1820-4.

Wadhwa, V., Chhabra, A., & Sametb, J. D. (2014). Melorheostosis Mimicking Synovial Osteochondromatosis. *Annals of Saudi Medicine*, 34(6), 547-550.